

Codman Case Presentation

Kyong S Min

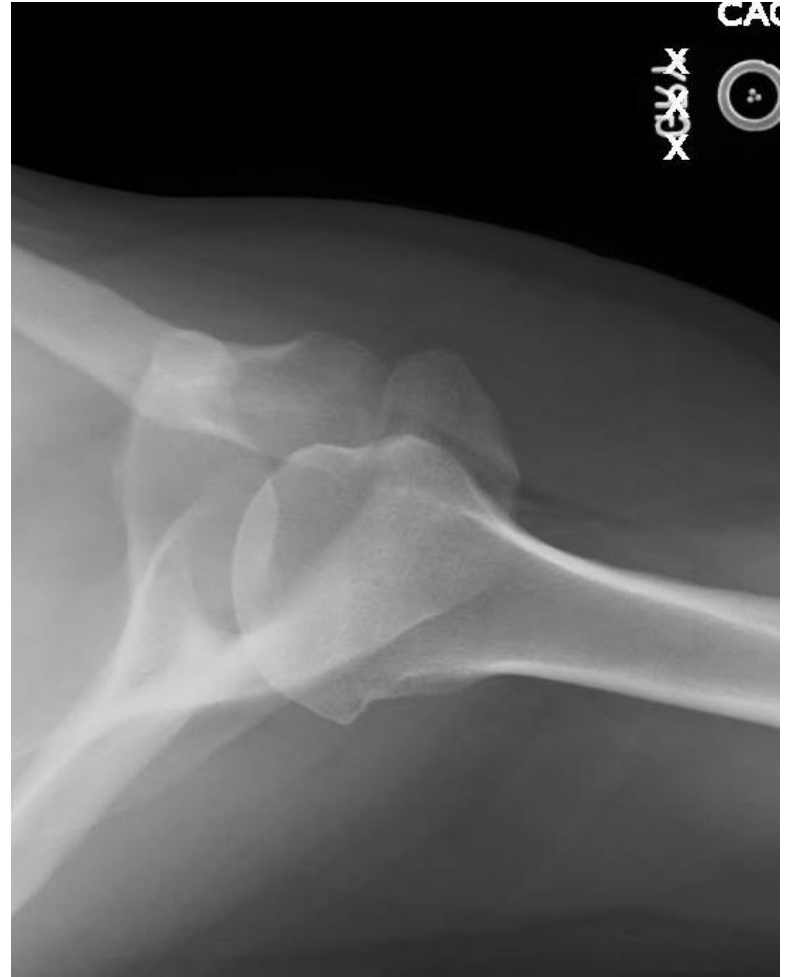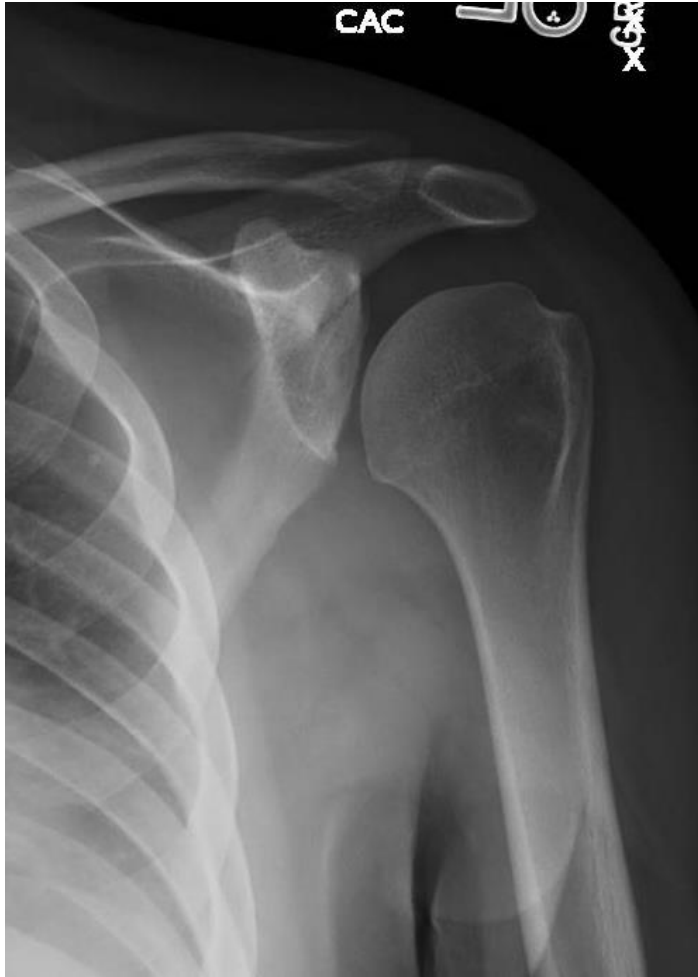10 SEPT 2018

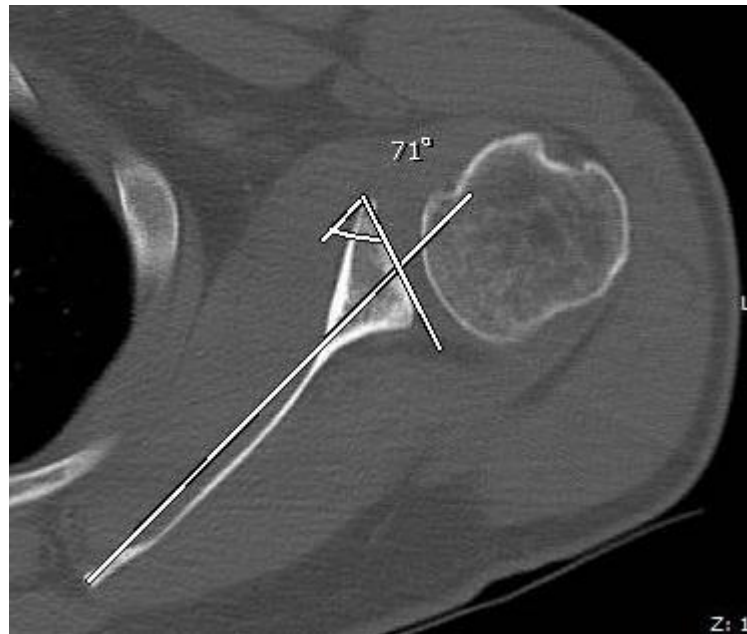
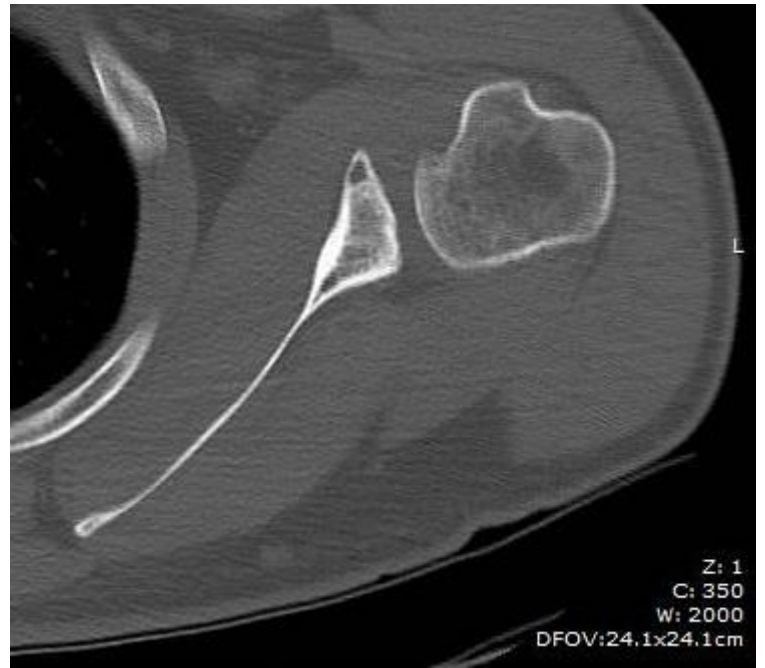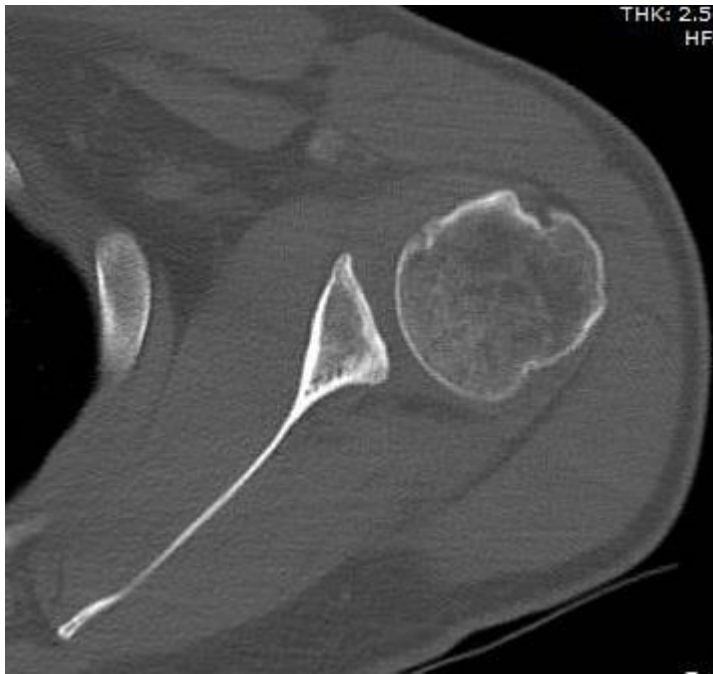31 year-old, active duty, sailor

- CC: Left shoulder pain following posterior dislocation
- HPI: Left shoulder pain since Jan 2018. Sustained a traumatic dislocation. States that his shoulder always felt “sloppy” since childhood and has been able to voluntarily dislocate it without pain. In Jan, he sustained a traumatic dislocation and was unable to self reduce. He now dislocates in his sleep.

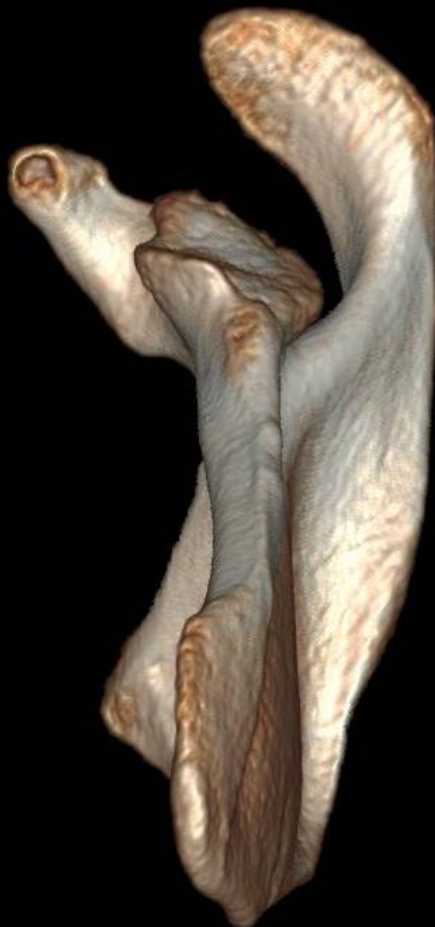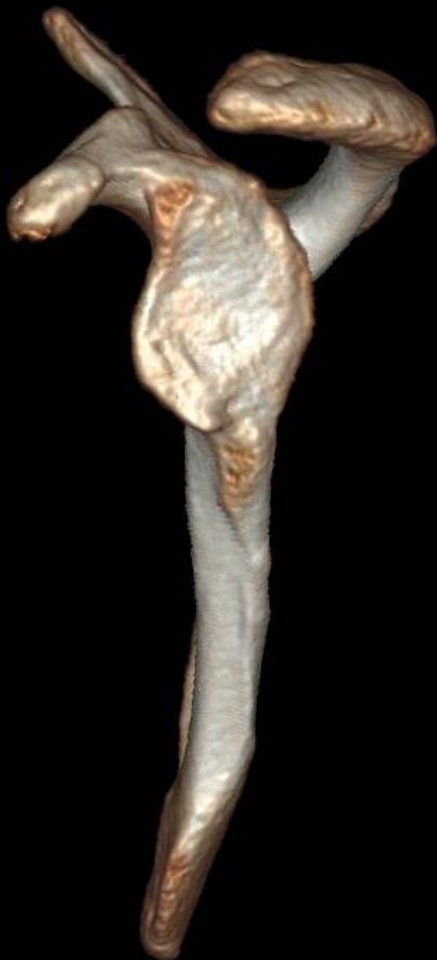Physical Exam

- AROM: FF 160, Abd 120, ER 90, IR upper lumbar
- PROM: FF 170, Abd 120
- No pain at AC joint with cross body examination
- Negative apprehension test, negative Kim
- RTC strength: ER 5/5, empty can 4-/5





filter



Summary

- 31 year-old with a Type C glenoid, mild OA, ~20 degrees of retroversion
- Painful posterior dislocation
- Treatment Options
 - Posterior glenoid reconstruction
 - Autograft iliac crest
 - Allograft distal tibia
 - Total Shoulder with Bone Graft or Augmented Glenoid
 - Hemiarthroplasty
 - Reverse Total Shoulder Arthroplasty
 - Any other suggestions?