

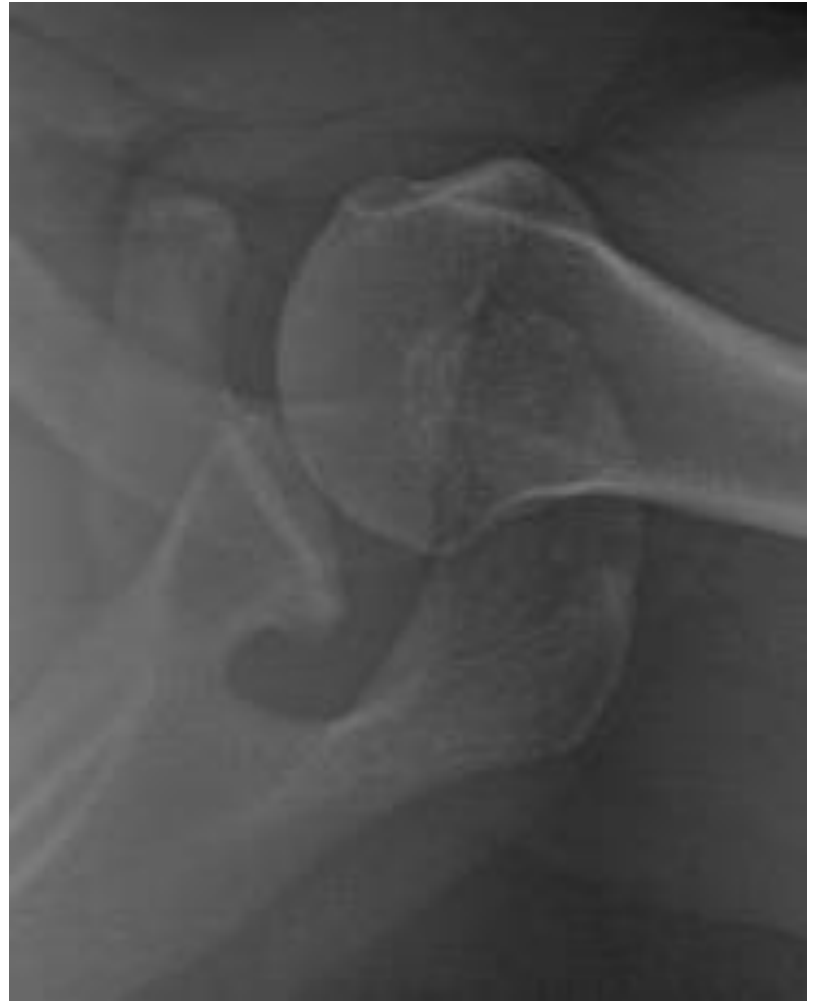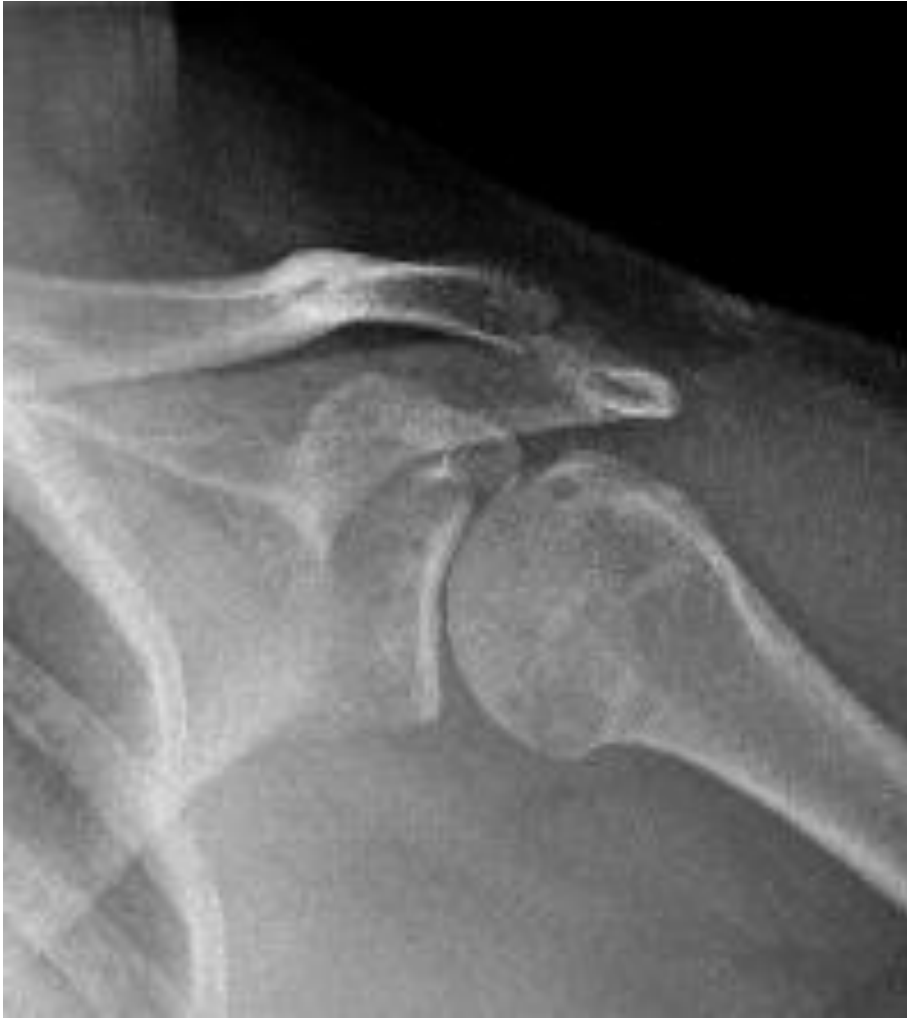Presentation for Codman Shoulder Society

JS

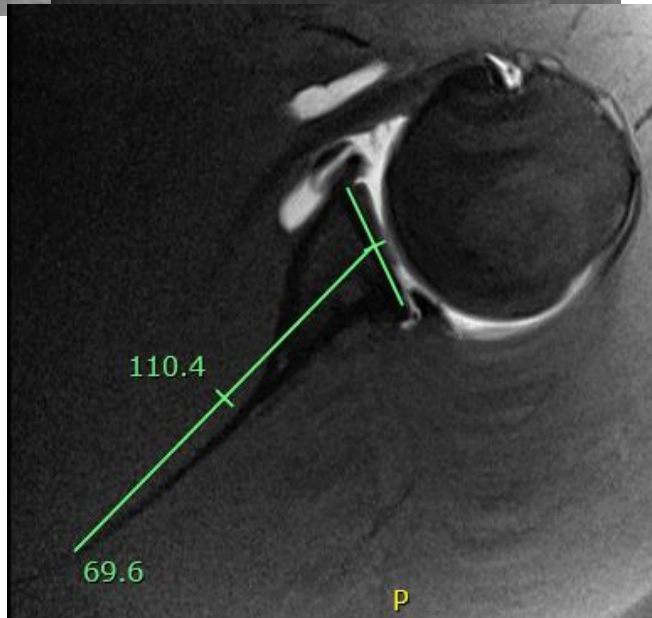
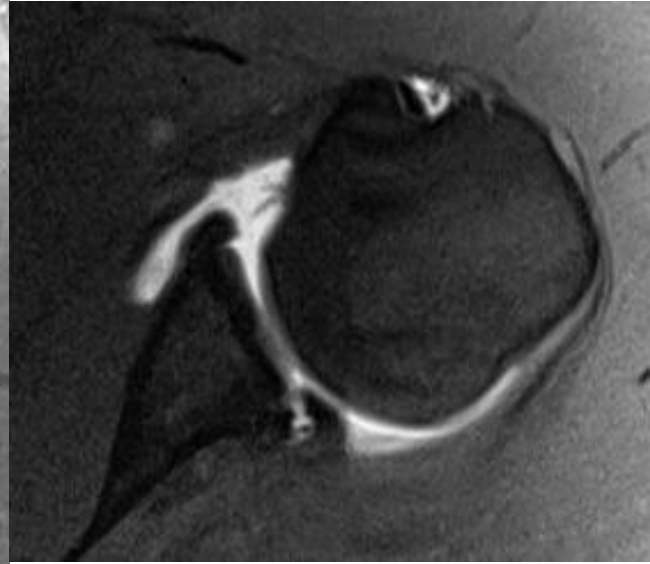
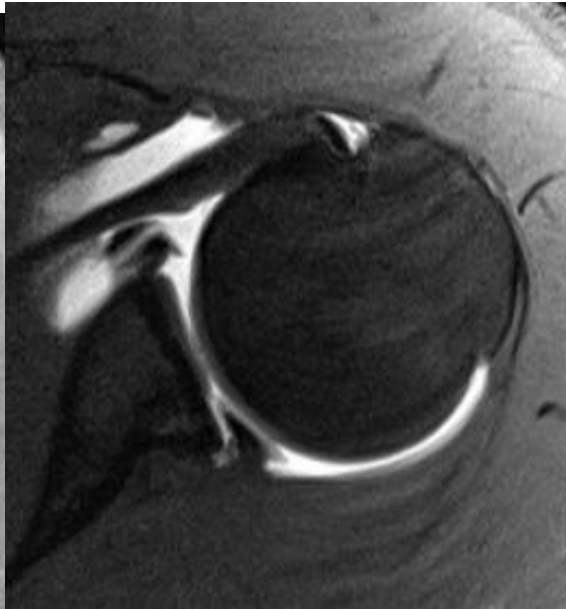
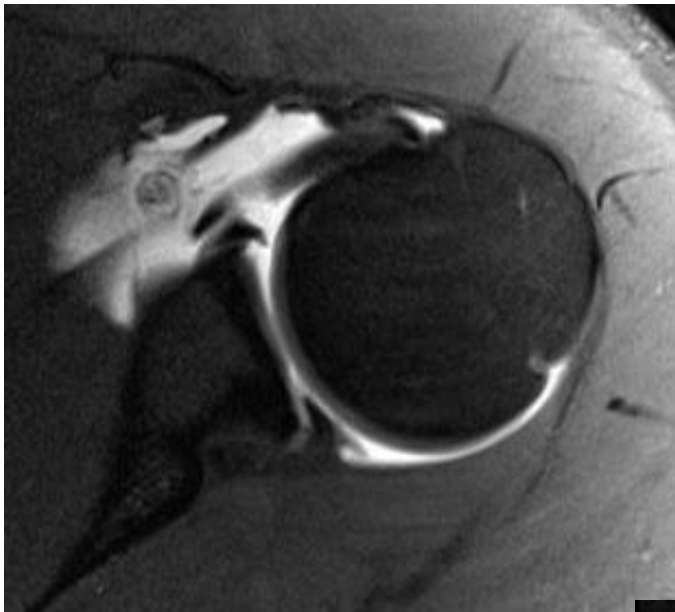
- ID: 26 yo RHD male with L shoulder pain x 4 years
- Previous posterior labral repair by another surgeon
- In 2014 recommended revision posterior labral repair but pain improved so declined to have surgery
- Now complains of constant pain since recent fall down stairs
- Worst with sleeping and reaching in the ABER position
- 6/10 pain at rest, 8-10/10 pain at worst
- SSV 50% (90% on Right)
- No recent PT or injections
- PMHx: None
- PSHx: R CC reconstruction, L SH arthroscopic posterior labral repair
- SH: Works as insurance broker, lives in Boston, MA
 - No tobacco
 - ETOH: socially
- Meds: Albuterol, Adderall, Toprol XL, Ativan
- Allergies: Oxycodone- vomiting

JS

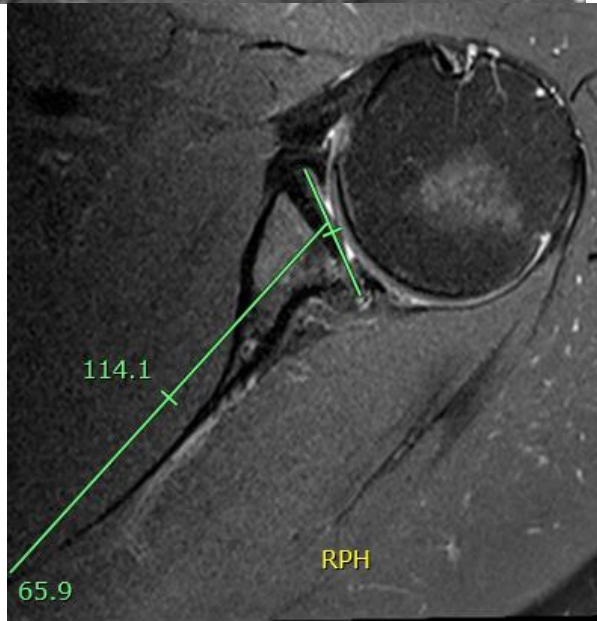
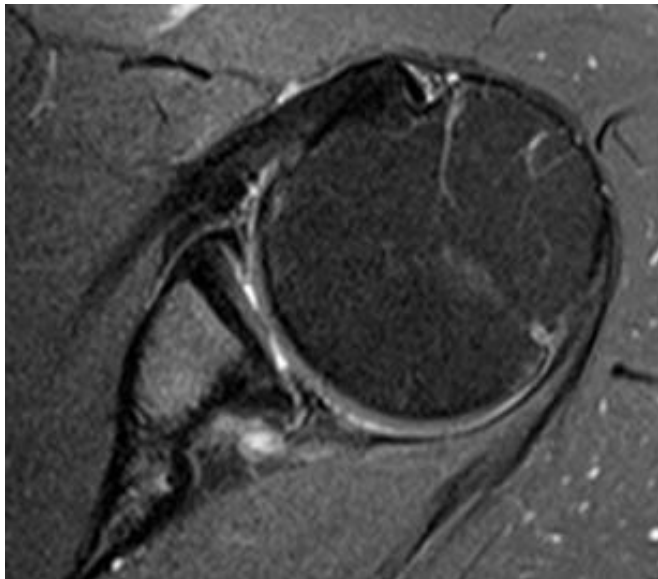
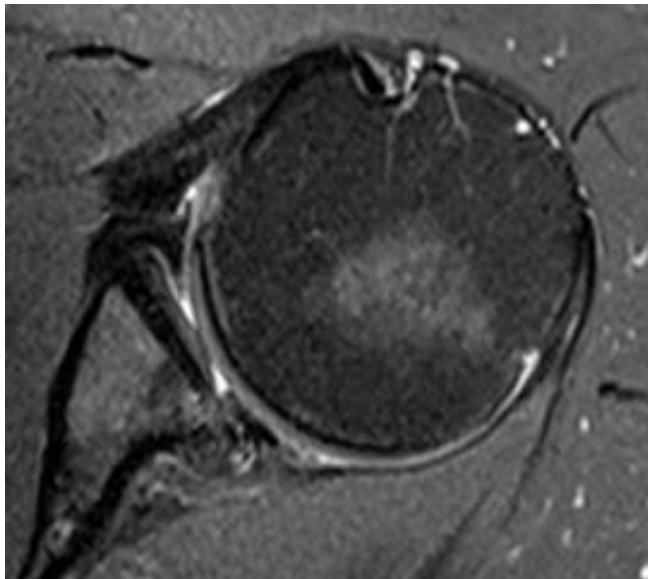
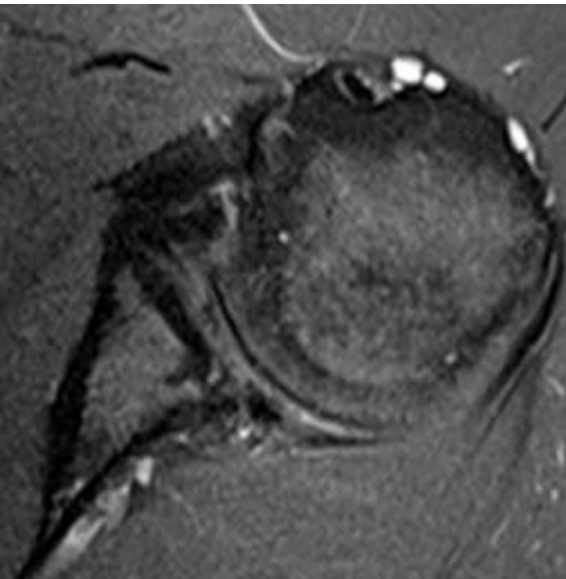
- Physical Exam:
 - 5'10", 260lbs (BMI 37) very muscular/physically fit
 - ROM R L
 - FF: 170/170
 - ABD: 140/140
 - ERN: 50 / 50
 - IR: T6 / T6
 - Special tests on LEFT:
 - + O'Briens
 - + Speeds
 - + Apprehension, relocation
 - + Posterior instability, + Jerk test
 - Guarding with load and shift but no frank shift
 - Strength testing on LEFT:
 - 5/5 strength Abd, ER, IR



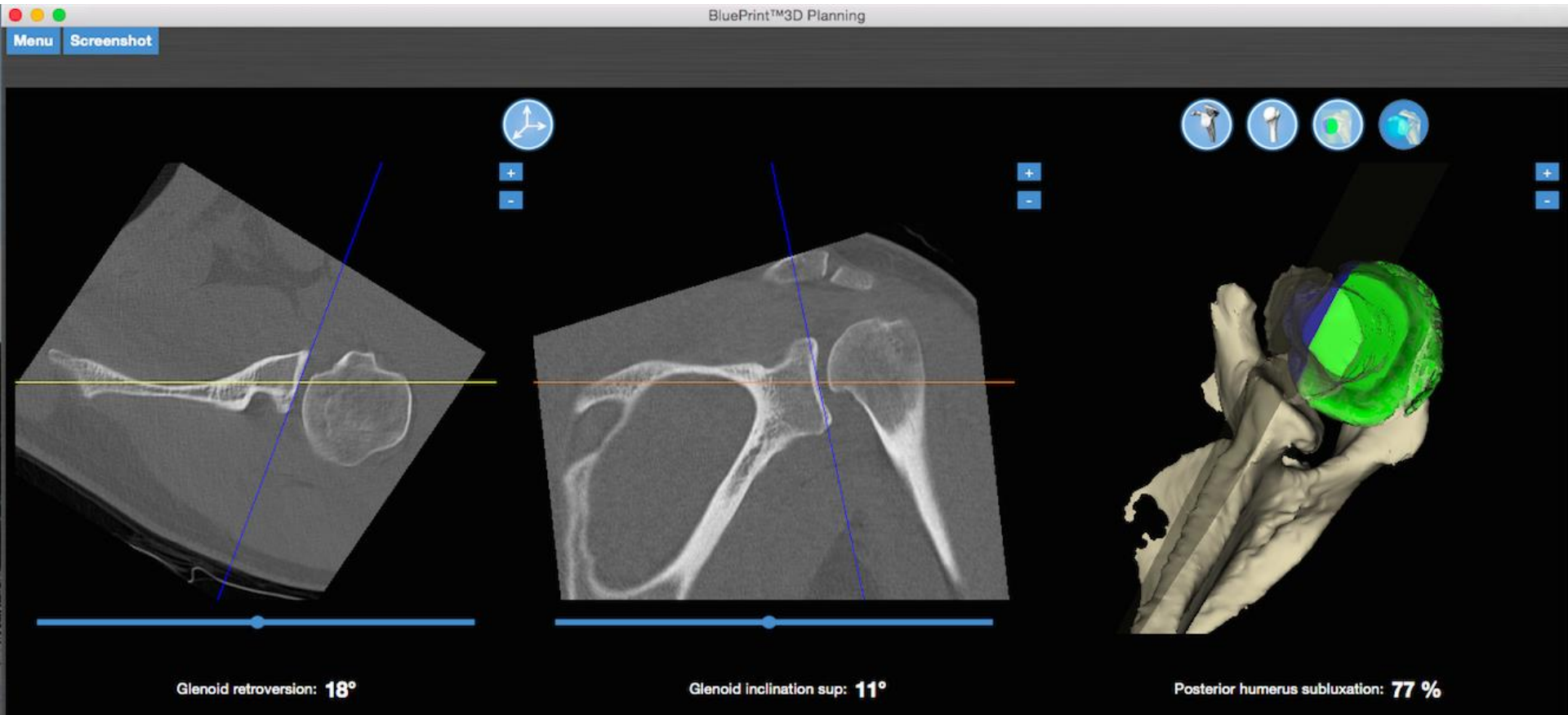
2014 MRI- approx 20deg retroversion



2018 MRI- approx 25deg retroversion



2018 CT scan with glenosys



JS

- ID: 26yo M with persistent L shoulder pain after failed posterior labral repair with increased glenoid retroversion over past 4 years and progressive evolution of posterior glenoid articular cartilage loss
- Surgical Options?
 - Revision Posterior Bankart
 - Osteotomy
 - Bone grafting
 - ??