

# Codman Shoulder Society Case Presentation

September 17, 2018

# MF 72 yo M

ID: 72 yo M with chronic right shoulder pain since late 2010 with extensive PSHx noted below. He felt a pop while moving his arm 2 weeks ago and notes new anterior and lateral pain and a “change in contour” of his right shoulder. SSV 30%.

PMHx: metastatic lung cancer (remission), HTN, HLD, PTSD, depression

PSHx: outlined below / Meds: Tylenol, Lipitor, Lasix, oxycodone / SHx: former smoker

## Surgical History:

2/16/11: right open RCR, SAD, biceps tenotomy, ORIF os acromiale

8/3/11: right revision arthroscopic RCR, SAD, removal of hardware (acromion)

9/18/15: right reverse total shoulder arthroplasty

1/19/16: revision ORIF os acromiale (nonunion), ICBG; greater tuberosity contouring for external impingement

4/19/16: removal of hardware (acromion)

5/2/16: open irrigation and debridement, tissue cultures to rule out infection negative

4/4/17: open irrigation and debridement; tissue cultures to rule out infection negative

9/12/17: acromionectomy with ICBG reconstruction and deltoidplasty (for mechanical symptoms and motion loss)

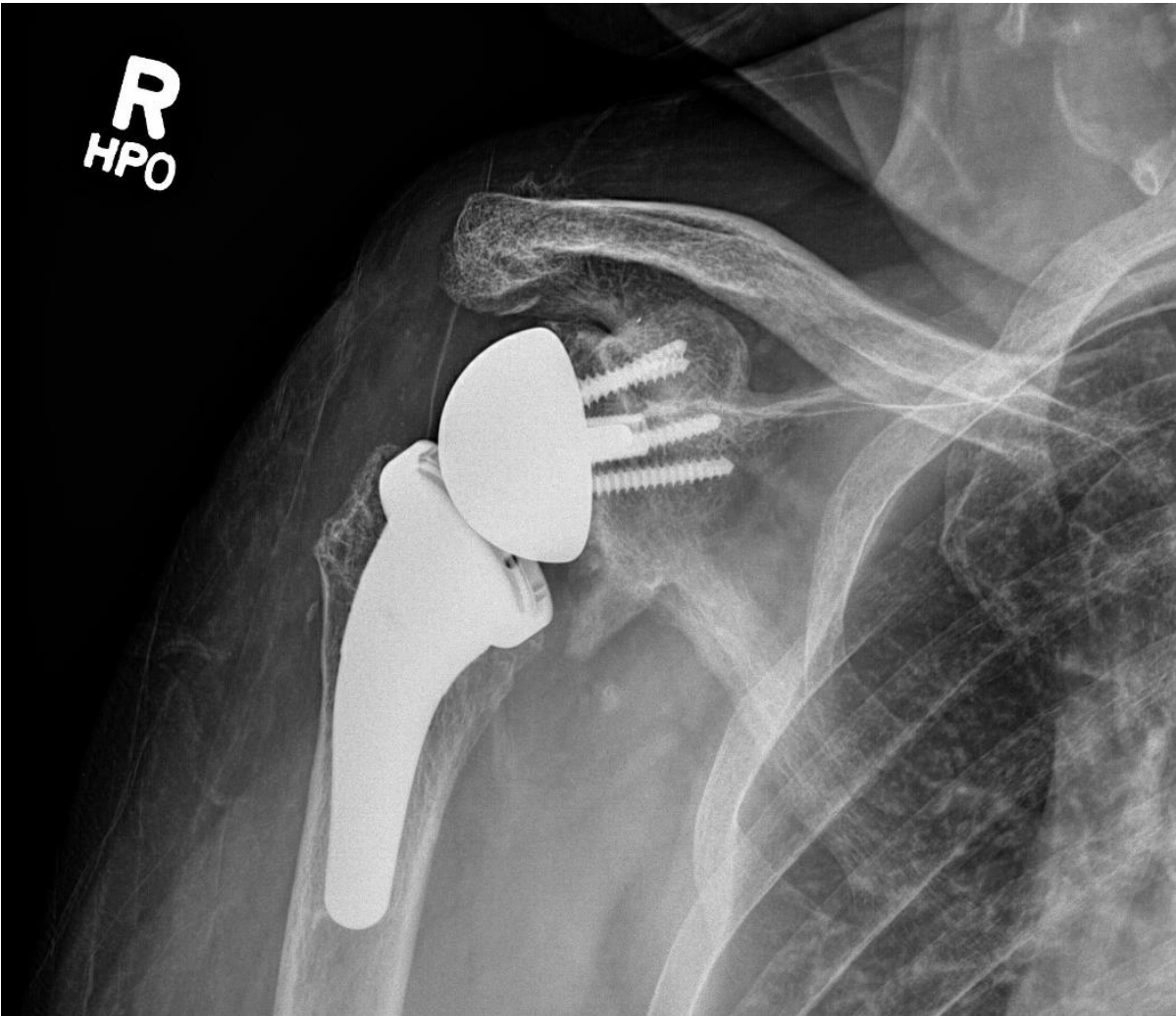
9/25/17: irrigation and debridement; tissue cultures to rule out infection negative

1/16/18: removal of hardware (acromion); revision deltoidplasty

# MF 72 yo M

- Most recent postoperative examination (~2 months following 1/16/18 OR)
  - Obvious acromial deformity with intact deltoid without palpable defect
  - Non-painful FF ~60 degrees active and ~100 degrees passive
  - Can bring hand to top of head
- Current physical examination (last week)
  - New tenderness to palpation along acromial edge with obvious deformity that appears similar to before; deltoid remains intact but with a new palpable defect appreciated anterolateral
  - Crepitus along acromial edge and tenderness with all planes of motion
  - Deltoid fires; strength 3 out of 5 compared to contralateral side
- Most recent imaging highlighted on following slides

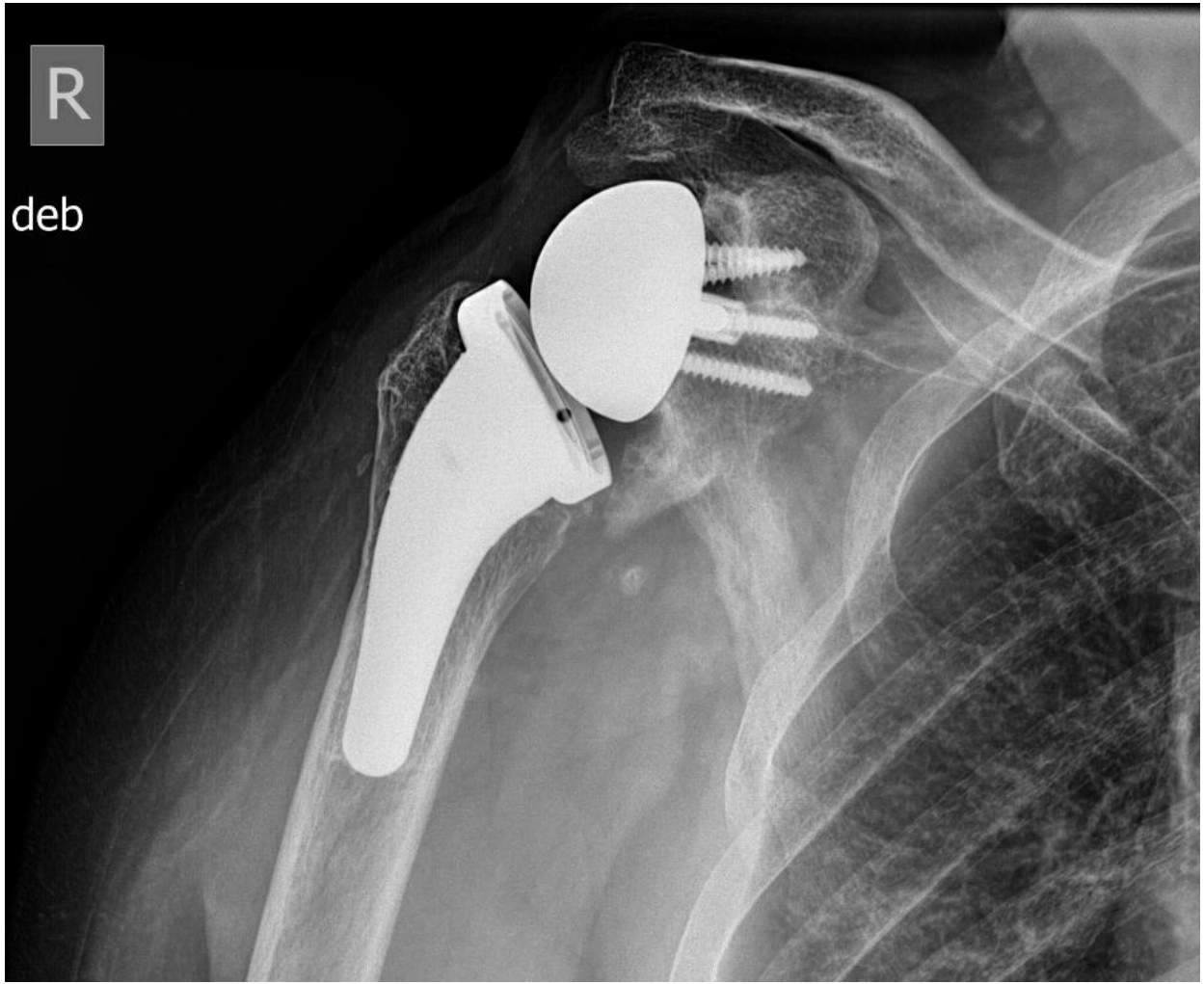**R**  
**HPO**



January 2018

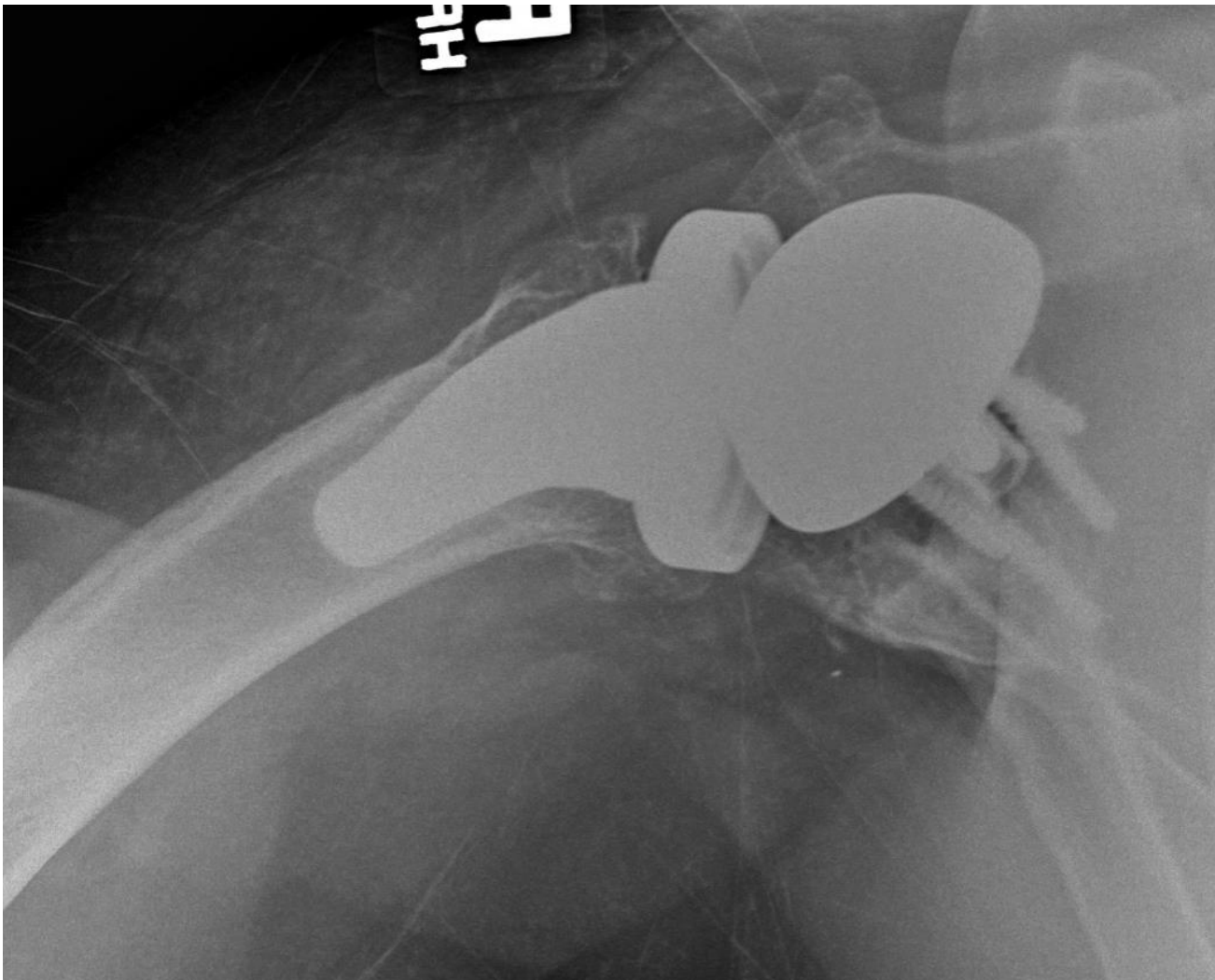
R

deb



August 2018

January 2018



August 2018

