

# Presentation for Codman Shoulder Society

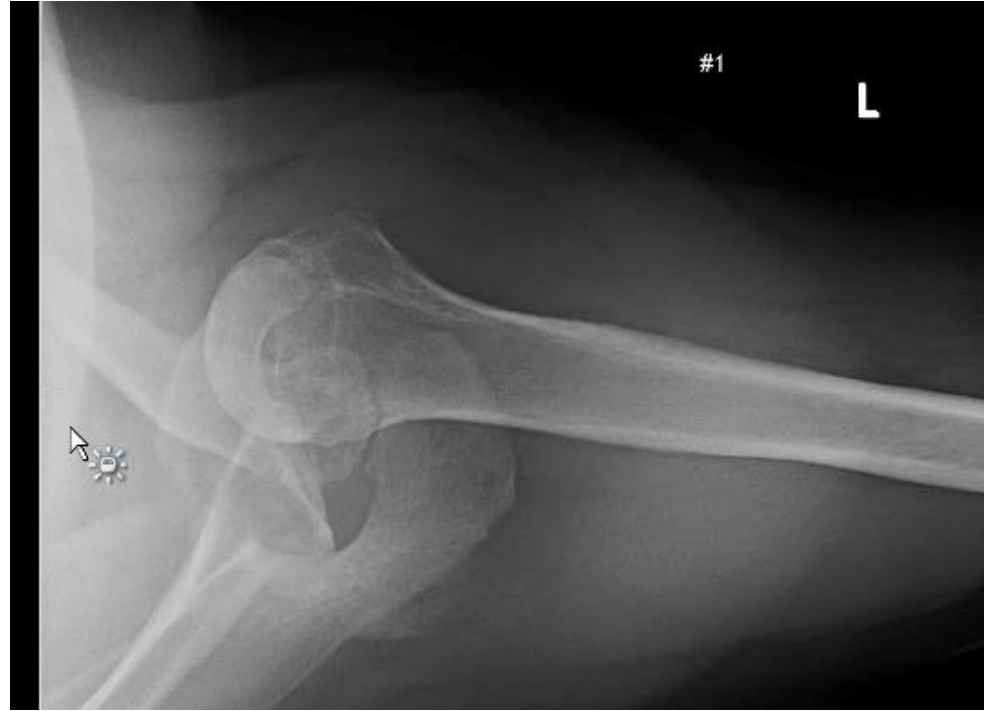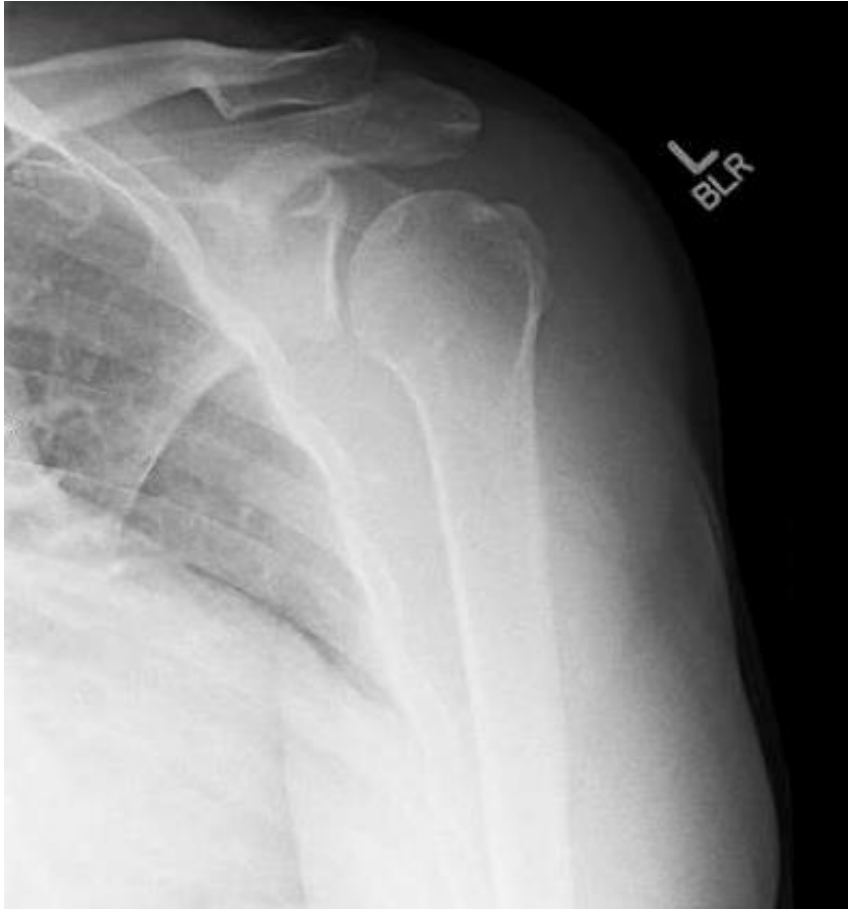# MM

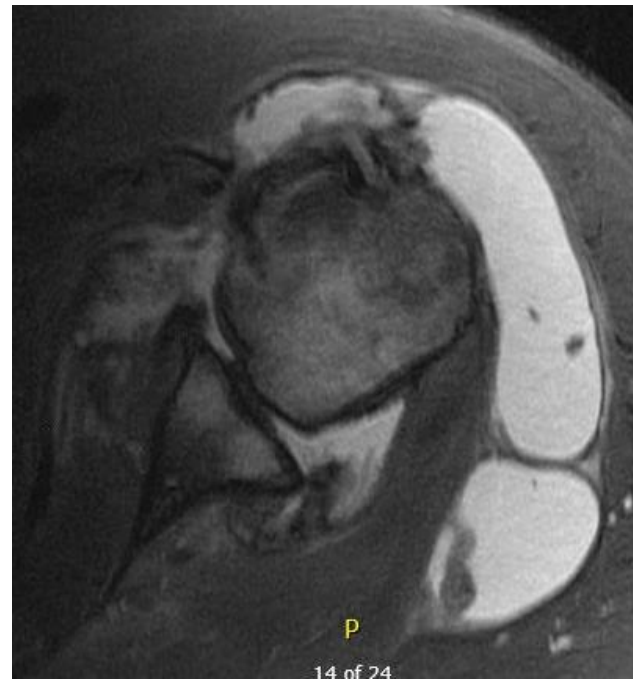
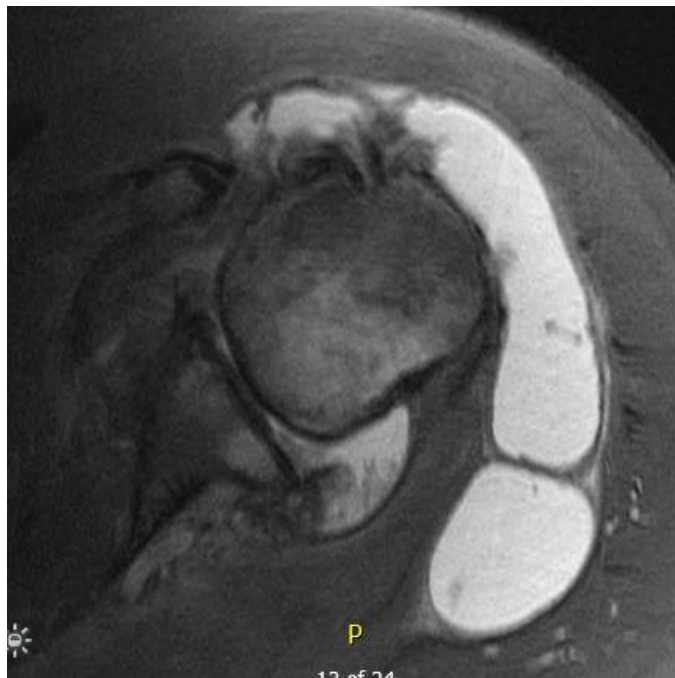
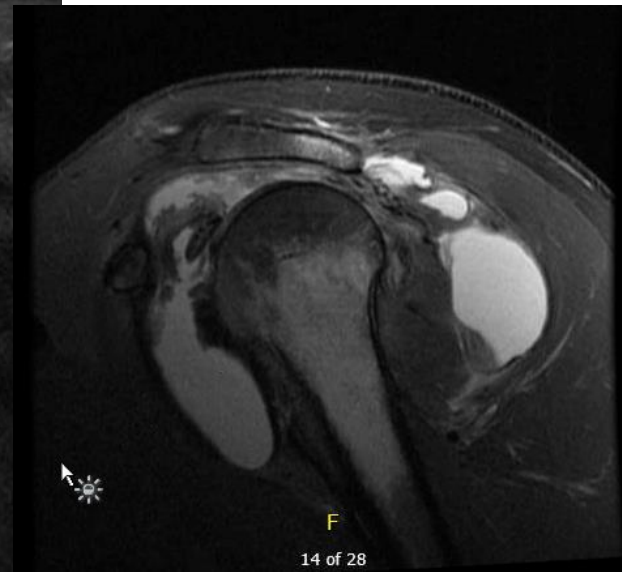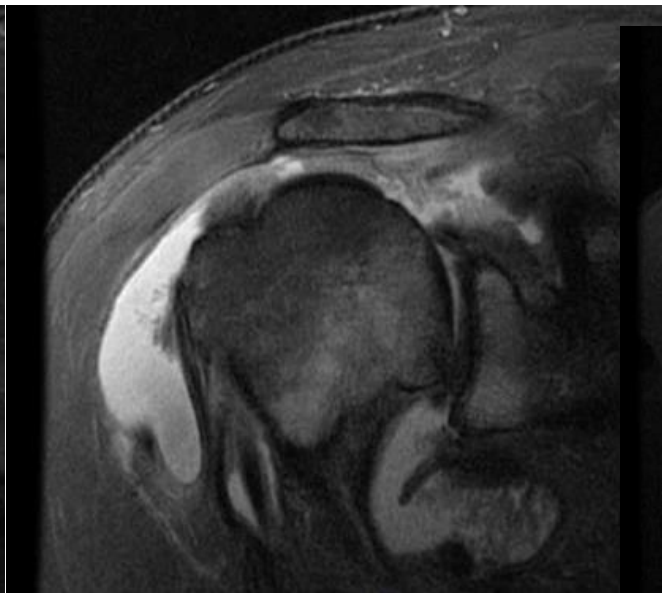
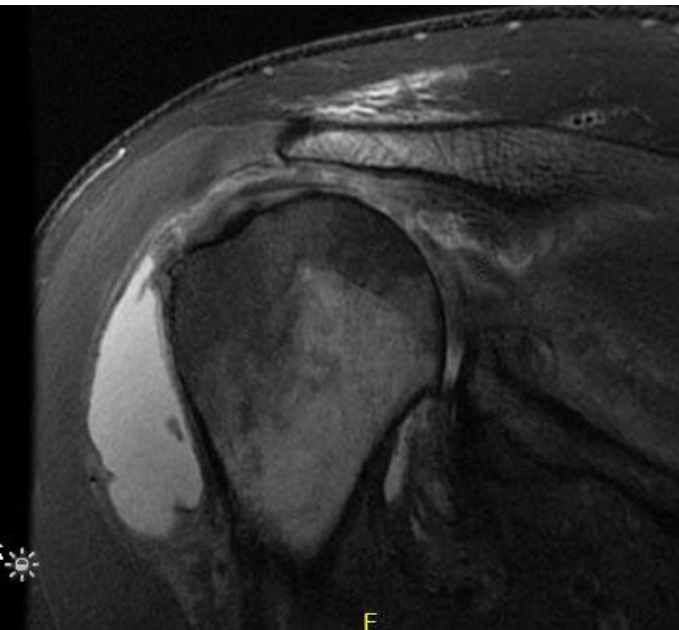
- ID: 40 yo LHD male with L shoulder pain
- HPI: Pain started end of 2016 after fall off deck
- Complains of pain and instability since injury
- No relief with corticosteroid injection
- Has history of Chiari Malformation and associated syrinx that has been surgically treated and is shrinking on MRI
- Has decreased sensation in left arm, wrist and fingers
- No response to neuropathic medication
- Neuro eval neg for CRPS
- +Night pain
- Pain 6-10/10
- SSV 30%
- PMHx: HTN, diabetes, Chiari malformation, syrinx
- PSHx: None
- SH: Works as warehouse supervisor, has been out of work for 6 months
  - Pack per day smoker, but reports he quit Nov 2017
  - ETOH: none
- Meds: None
- Allergies: NKDA

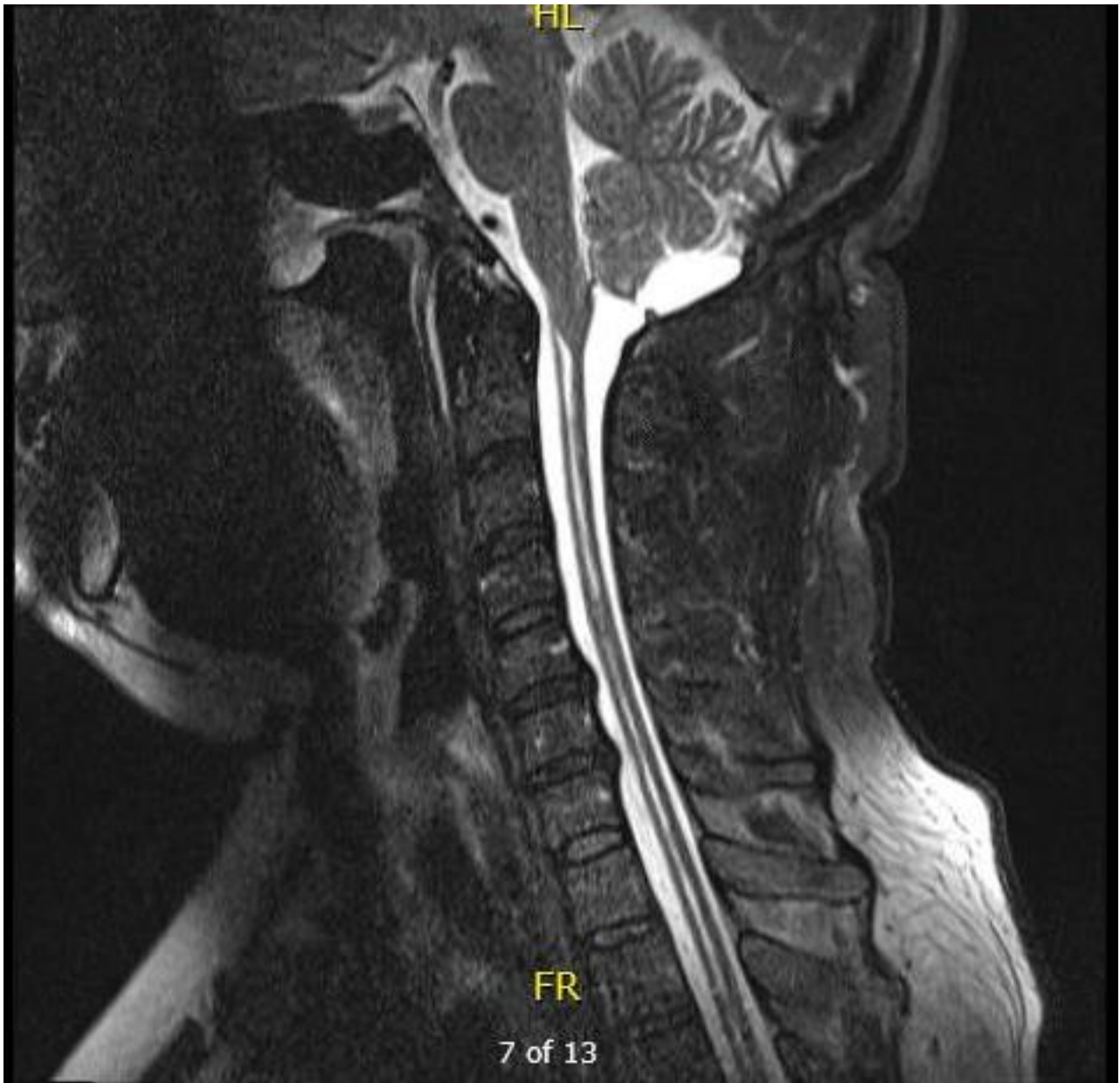# MM

- Physical Exam:
  - 5'7", 227lbs (BMI 35)
  - Crepitus with shoulder ROM
  - Decreased sensation in M/R/U nerves compared to contralateral
  - ROM


	R	L
• FF:	160/150	
• ABD:	140/140	
• ERN:	60 / 60	
• IR:	L1 / Sacrum	
  - Special tests:
    - + Cross body abduction
    - + Hawkins
    - + Neer's
    - + Belly press
    - + Apprehension, relocation
  - Strength testing
    - Abd 4/5, ER 4/5, IR 4/5







# MM

- ID: 40yo M with persistent L shoulder pain and instability in the setting of syrinx with concern for Charcot joint
- Surgical Options? Left shoulder arthroplasty versus fusion