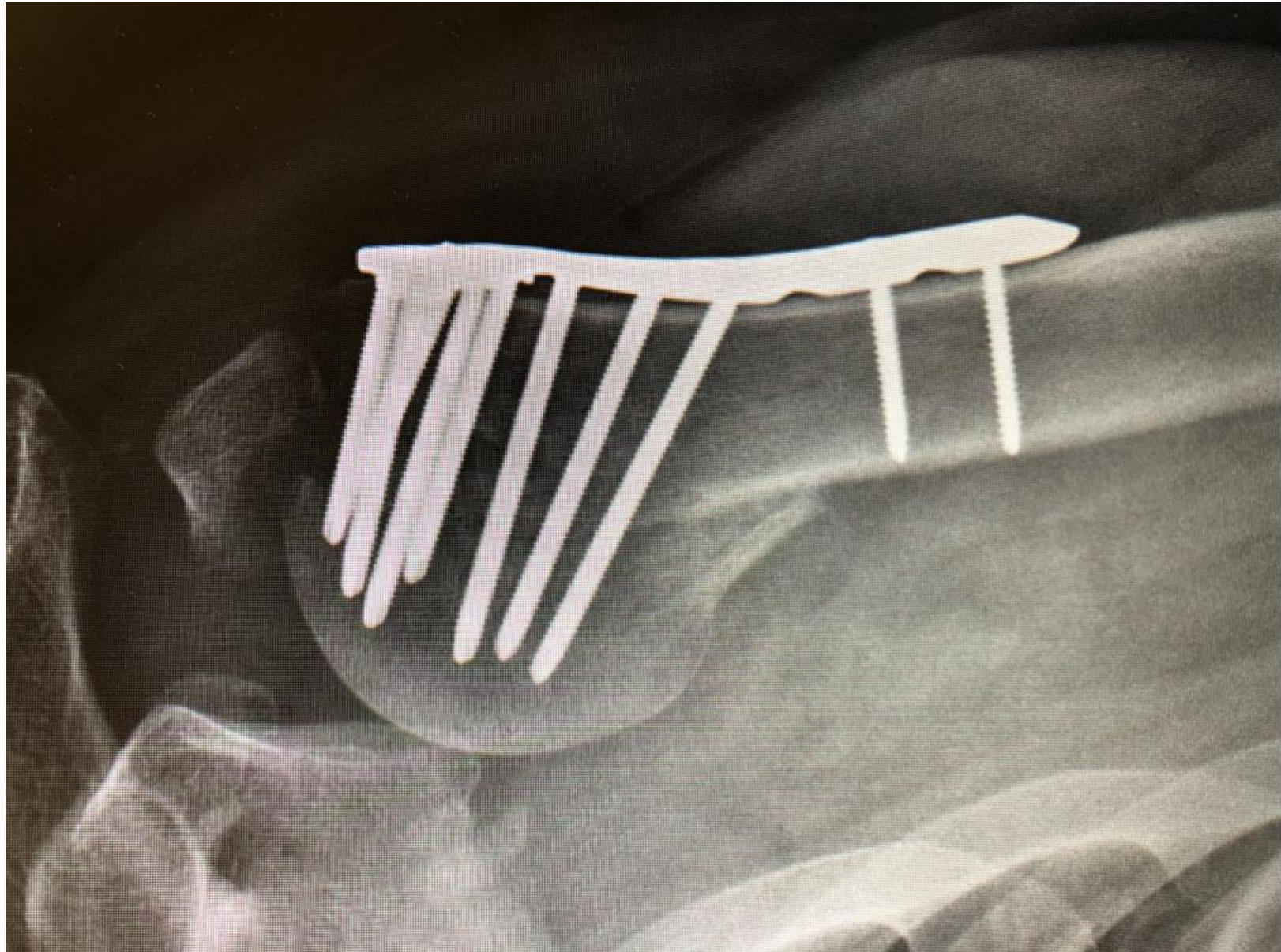


Case Presentation for Codman Shoulder Society

Case

- 54 yo healthy nurse fell in North Carolina and had ORIF 8 weeks ago after frx dislocation.
- Came to ER in NY 2 weeks postop with effusion. Another ortho Surgeon washed him out (+ staph and E. coli), left plate in place and had ID put picc line and IV ABX x 6 weeks.
- Now almost no shoulder function now and terrible pain



Plan

- Remove plate, treat with another 6 weeks of IV ABX then revise to reverse
- Is there any value in doing a ROH and spacer as my first procedure?
- Other Options?